

# FATAL MERCURY INTOXICATION IN A DENTAL SURGERY ASSISTANT

T. A. COOK<sup>1</sup>, M.B., CH.B.  
PETER O. YATLS<sup>1</sup>, M.D., M.R.C.PATH.

**A 42-year-old dental surgery assistant with at least a 20-year history of exposure to mercury developed a rapidly fatal nephrotic syndrome. The high levels of mercury in the kidney, estimated by neutron activation analysis and demonstrated histologically, indicate that this was the result of mercury intoxication. Some unique features of the case are described and discussed. The warning is given that the risks of exposure to mercury in the dental surgery are not trivial.**

## Introduction

THE hazard of mercury poisoning in the dental surgery has been frequently discussed and there have been several investigations into this problem. It has, however, been stated (Grossman and Dannenberg, 1949; Frykholm, 1957) that volatilised mercury in the air of the dental surgery, which is the main route by which mercury is absorbed, presents no serious risk to dental surgeons and their nurses.

Nixon and Smith (1965) have restated the possible hazard to health presented by mercury in the dental surgery in a study in which there were significantly elevated amounts of mercury in the hair and nails of female dental assistants as compared with controls.

This paper will indicate that mercury implies a threat not only to the health but also to the lives of those working in dentistry.

## Case Report

A 42-year-old woman had been a dental surgery assistant for at least 20 years, and during this time had regularly handled mercury in compounding a dental amalgam which contained just under 40 per cent of metallic mercury.

As far as can be ascertained she was completely well with no stigmata of chronic mercury poisoning until she became suddenly ill with vomiting, pain in the right lumbar region of the abdomen, oedema of the face and legs, and the passing of dark urine. The syndrome was not that of congestive cardiac failure. No history of preceding upper respiratory or other infection was obtained. The persistence of these symptoms over the next 6 days resulted in her being admitted to hospital.

Upon admission she was found to have heavy albuminuria although the serum proteins were at this time still normal. Serum sodium was 111

mEq and chloride 77 mEq per litre; the blood urea was elevated to 280 mg per cent. A diagnosis of nephrotic syndrome was made and treatment with steroids and diuretics initiated. However her general condition rapidly worsened as she passed into more serious renal failure. She was therefore transferred 17 days later to the Manchester Royal Infirmary. She was by this time disorientated and drowsy, with a serum sodium of only 95 mEq and chloride of 60 mEq per litre and a blood urea of 225 mg per 100 ml. In spite of vigorous medical therapy and repeated peritoneal dialyses she continued to deteriorate generally: even after rehydration and electrolyte replacement the blood urea was still 115 mg per 100 ml, sodium 138 mEq, potassium 3.0 mEq and chloride 92 mEq per litre. On the last day of her life serum potassium varied between 1.4 and 3.0 mEq per litre. There were azotæmic convulsions followed by cardiac arrest, and she died 4 days after the transfer to the Manchester Royal Infirmary. Urinary mercury levels were not examined.

## Findings

Autopsy was performed 30 hours after death. There was peripheral and pulmonary oedema and a mild generalised peritonitis as a result of the repeated dialyses. The kidneys were of normal size (R 110g; L 140g) and appeared macroscopically normal in all respects except for perhaps slight pallor generally. No significant abnormality was found in any other organ at autopsy.

Light microscopy of sections of kidney showed no abnormality of glomeruli or blood vessels (fig. 1). The tubules contained protein casts and there was some shedding into the tubular lumen of the epithelial lining cells of the proximal and distal convoluted tubules and the collecting tubules. Occasional mitotic figures were seen in the cells still lining the tubules.

<sup>1</sup>Department of Pathology, University of Manchester.



FIG. 1.—Section of kidney from the case showing a glomerulus which is apparently normal and some thinning of tubular epithelium. H. and E.  $\times 300$ .

Similar flattening of the epithelium of the proximal convoluted tubule, suggestive of a healing lesion, occurred in case 9 of Joekes *et al.* (1958).

The kidneys were fixed in 10 per cent formalin. Staining techniques to demonstrate mercury were applied to sections of kidney. Brandino, and Tirmann and Schmeltzer methods were used, both of which depend on the conversion of mercury in the tissue to the insoluble sulphide. The latter technique is, of course, more usually applied to the demonstration of iron in tissue; here the presence of mercury—for mercuric chloride is often added to formalin to expedite the fixation of tissue—is a drawback as the precipitated mercury obscures the iron. But in this case advantage was taken of this phenomenon. A simple Prussian blue staining for iron was in fact negative.

Mercury was found widely in the kidney (fig. 2) in fine particles within the epithelial and

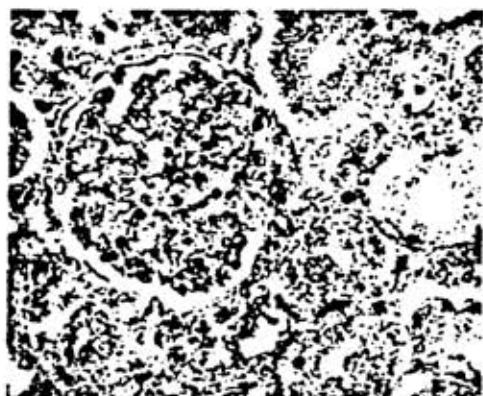


FIG. 2.—Section of kidney from the case, stained to show the presence of mercury. This is seen as black granules in the glomerulus and in the tubular epithelium. Tirmann and Schmeltzer.  $\times 250$ .

endothelial cells of the glomerulus and Bowman's capsule, the proximal and distal convoluted tubules and the walls of arteries and capillaries. A slightly lesser amount was present in the straight parts of the tubules and the collecting tubules.

A similar picture was not seen when the same staining technique was applied to normal control kidneys and sections of normal kidney fixed in corrosive sublimate formalin show the mercury to be randomly scattered in an extracellular situation, not dispersed in fine particles but in much larger aggregates (fig. 3).

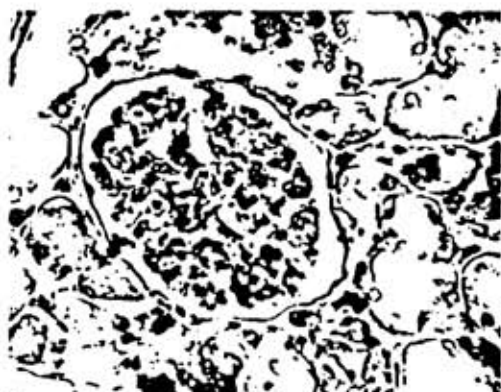


FIG. 3.—Section of kidney from a control case, the tissues having been fixed in mercuric chloride formalin. The mercury deposits are seen as fairly large black masses, quite unlike the fine distribution seen in figure 2. Tirmann and Schmeltzer.  $\times 250$ .

Dried portions of the formalin-fixed kidney were subjected to neutron activation analysis for mercury. Three control kidneys, similarly fixed, were simultaneously likewise analysed. The controls were obtained from patients aged 12, 19 and 43 whose kidneys were normal at autopsy and who had had no contact with mercury.

The results of the analysis are as follows:

	Mercury by weight
This case	520 ppm
Control 1	5 ppm
Control 2	9 ppm
Control 3	2 ppm

Sections of kidney were also examined by electron microscopy. Unfortunately, by the time that the blocks were removed for processing, too great post-mortem change had occurred for any useful information to be obtained from this study. This was a particular disappointment for no satisfactory account exists of the ultrastructural renal changes in mercury intoxication.

## Discussion

A study of relevant literature suggests that this case is unique.

Acute renal failure as a result of mercury intoxication is uncommon even when suicide is attempted by the ingestion of mercuric chloride. Patients either succumb rapidly to shock or die, or even more commonly survive after a period of oliguria. The kidneys of those dying in acute renal failure as a result of mercury poisoning appear pale and swollen in a non-specific way. On microscopy there is necrosis of the proximal convoluted tubules.

A rapidly fatal nephrotic syndrome has not before been described in mercury poisoning. While the presence of mitotic figures in the epithelial cells lining the tubules in this case suggests that there has been some degree of tubular necrosis, nevertheless the acute urinary suppression syndrome did not occur; rather the nephrotic syndrome.

More commonly, mercurial kidney lesions occur only after prolonged exposure to mercury in the form of mercurial diuretics, teething powders, ointments containing mercury, or as an industrial hazard. The kidneys of those cases dying in these circumstances have shown damage in the proximal and, more rarely, the distal convoluted tubules (Preedy and Russell, 1953; Burston *et al.*, 1958; Riddle *et al.*, 1958); glomeruli are spared. In chronic mercurial poisoning the clinical picture is that of the nephrotic syndrome. It is of interest that both in chronic mercury poisoning and in the case described in this paper the nephrotic syndrome is associated with tubular damage but normal glomeruli. This syndrome is usually associated with glomerular rather than tubular damage.

No firm conclusion can be reached as to whether this case represents acute or chronic mercury intoxication. More probably it is the latter. The absent history of previous evidence of mercury poisoning may be disregarded. Because of the wide range of normal behaviour, irritability, excess salivation or tremor might well pass unnoticed.

The amount of mercury present in the kidney is considerable. This was probably accumulated over twenty years. Most dental surgery assistants do not practise their profession for such an interval of time. This is the first reported

case of fatal mercury intoxication in a dental surgery assistant. Possibly the relative brevity of the dental surgery assistant's career has effected this, but more probably evidence of mercury intoxication has not been sought.

Only speculation is possible as to the cause of the rapid onset of her rapidly fatal renal failure. There may have been an acute rise in the amount of mercury in the tissue as a result of a sudden increase of mercury in her working environment. For example, mercury might have been spilt and disregarded. On the other hand she may have suddenly developed a sensitivity to mercury without there being any change in tissue mercury levels. For Kazantzis *et al.* (1962) have described reversible albuminuria occurring in industrial workers exposed to mercury without the supervision of the full clinical picture of the nephrotic syndrome. They have suggested that it is the development of idiosyncrasy to mercury that plays a significant role in the development of the syndrome.

Every attempt appears to have been made by the clinicians to correct the severe biochemical upset, but with little effect. The disease process did not appear to be amenable to that kind of treatment on its own. Possibly more might have been achieved by the addition of dimercaprol to the therapeutic regime.

Little doubt can remain that the rapidly fatal renal failure in this case was the result of mercury intoxication. Once again a warning is served that dental surgeons and their surgery assistants are exposed to the hazard of mercury intoxication. Every effort should be made to ensure a safe working environment.

## ACKNOWLEDGMENT

Our thanks are due to Professor G. S. Nixon of the Turner Dental School, University of Manchester, for his helpful advice in the investigation of this case.

## REFERENCES

- Burston, J., Darmady, E. M., and Stranack, F. (1958) *Brit. med. J.*, **1**, 1277.
- Frykholm, K. O. (1957) *Acta odont. scand.*, **15**, suppl. 22.
- Grossman, L. I., and Dannenberg, J. R. (1949) *J. dent. Res.*, **28**, 435.
- Joekes, A. M., Heptinstall, R. H., and Porter, K. A. (1958) *Quart. J. Med.*, **27**, 495.
- Kazantzis, G., Schiller, K. F. R., Ascher, A. W., and Drew, R. G. (1962) *Quart. J. Med.*, **31**, 403.
- Nixon, G. S., and Smith, H. (1965) *J. Oral Ther. Pharm.*, **1**, 512.
- Preedy, J. R. K., and Russell, D. S. (1953) *Lancet*, **ii**, 1181.
- Riddle, M., Gardner, F., Beswick, I., and Filshie, I. (1958) *Brit. med. J.*, **1**, 1274.